

J. Perinat. Med.
29 (2001) 335–343

Bedside functional imaging of the premature infant brain during passive motor activation

Susan R. Hintz¹, David A. Benaron¹, Andrew M. Siegel², Anna Zourabian²,
David K. Stevenson¹, and David A. Boas²

¹Biomedical Optics Group, Division of Neonatal and Developmental Medicine, Stanford University School of Medicine and Hansen Physics Laboratory, Palo Alto, California, and ²Massachusetts General Hospital NMR Center, Harvard University, Charlestown, U. S. A.

1 Introduction

Brain imaging systems have traditionally been used to identify and delineate morphologic abnormalities. However, more recently, functional imaging techniques have come to the fore, which use brain metabolite concentration to map brain function [18], or take advantage of the fact that regional blood flow (rCBF) and hemoglobin oxygen saturation changes occur in response to neural and electrical activation such as that caused by moving, sensing or thinking [23,28]. Unfortunately, efforts to use techniques such as single photon emission computed tomography (SPECT), positron emission tomography (PET) and functional magnetic resonance imaging (fMRI) routinely in critically ill patients have proven difficult. Although successful in many cases, and potentially of use in the future to direct therapeutic interventions and provide prognostic information, these modalities are not feasible in many intensive care situations due to the problems and hazards of moving extremely unstable patients from the intensive care unit. In addition, the critically ill patient is likely to have a rapidly changing clinical status, possibly impacting upon cerebral functional changes. Thus, a continuous functional imaging method could be of benefit in these scenarios.

Red and near-infrared light can pass easily through structures such as the skull, penetrating the brain and allowing for assessment of changes in regional blood volume and hemoglobin oxygen saturation.

Adult human brain functional imaging studies have previously been reported using continuous wave spectroscopy [22]. Using our time of flight and absorbance device (TOFA), we have also reported optical functional images of the adult motor cortex during hand movement, which showed good spatial agreement with fMRI [11]. In addition, we have demonstrated that intraventricular hemorrhage (IVH) can be successfully detected in the neonate using optical scanning [12], and in an infant with stroke, that optical imaging highlighting local decreases in oxygenation correlate well with CT imaging [11]. For the clinical studies presented here, we used a diffuse optical tomography system (DOTS), which is a portable, compact, fast and cost-effective bedside near-infrared imaging system. The DOTS has the advantage of all near-infrared systems in that it uses a safe and non-ionizing form of radiation, but it is also a relatively inexpensive, fast, portable and potentially continuous monitoring system.

In this report we discuss the preliminary data examining bedside, real-time, continuous functional images of the premature infant brain in the NICU using near-infrared technology.

2 Methods

2.1 DOTS Device

Several years of bench-top feasibility studies is driving the development of systems optimized for

clinical applications. Most importantly, it has been necessary to develop instruments that can make hundreds of independent measurements in as short a time period as possible without sacrificing signal quality. To that end, a portable diffuse imager (DOTS) was developed by Siegel et al. [30]. Previous reports have shown good spatial agreement using this device with phantoms over a range of scattering and absorption conditions, and have investigated cerebral functional imaging during neuromuscular stimulation in paralyzed adult rats [30]. A similar device has been reported by Chance et al [2]. Since clinical measurements in the hospital environment was the goal of the system development, a severe stray-light rejection requirement was placed on the design; specifically, a 50 picowatt signal needed to be detectable under an ambient light background in the microwatt range. Therefore, a coherent detection technique was employed to reject room light contribution and reduce $1/f$ electronic noise. This technique requires that the source be intensity-modulated in some known fashion, usually in the form of a 50% duty cycle waveform. In the case of the DOTS, current modulation through laser diodes at 780 nm and 830 nm wavelengths was used. The raw photodetector signal was first highpass filtered to remove low frequency flicker noise and DC drift, and it was then fed into a double-balanced mixer. The mixer, which is gated by the same modulator that controls the source intensity, synchronously rectifies the modulated source signal, which then appears as a pulsating DC voltage at the mixer output. All other spurious optical signals, which are not phase-coherent to the source will exit the mixer in the form of frequency-shifted AC signals. A lowpass filter placed at the output of the mixer is used to both eliminate these incoherent signals and to filter out the pulsations in the DC signal, leaving a DC voltage proportional to the magnitude of the source energy detected. The time constant of the lowpass filter controls the post-detection bandwidth, which determines the rate at which intensity changes can be detected.

Laser diodes at 780 nm and 830 nm (Thor Labs, Newton, New Jersey, and Reprtron Electronics, Tampa, Florida) are time-shared with the sequence controlled by a portable lap-top computer (Dell Computer Corporation, Round Rock, TX).

The detectors are monolithic photo-diode/preamplifier chips (Burr-Brown, Tucson, AZ). The laser diodes are modulated at 2 kHz to enable coherent detection. The present system acquires data from 9 sources and 16 detectors, a total of 144 independent measurements per wavelength in approximately 3 seconds.

2.2 Infant probe

The optical probes used for these studies were custom-built (figures 1 and 2). Acrylic (PMMA) fibers, 1 mm in diameter were used for these probes due to ease of polishing, flexibility and lower weight. The fibers were approximately 2 meters in length to allow proper positioning of the system away from the patients and monitors. The 9 source optical fibers were arranged in a 3×3 grid and the 16 collection fibers were arranged in a 4×4 grid. The optical source fiber grid was arranged within the collection fiber grid (see insets of figures 3 and 4 for grid diagrams). The fibers were embedded in custom-made RTV silicone caps (GE Company, GE Silicones, Waterford, NY) slightly larger than the dimension of the fiber grids. For the initial studies, the grid dimension was $6 \text{ cm} \times 4 \text{ cm}$, however with further probe development, subsequent probe grid dimensions were changed to $8 \text{ cm} \times 5 \text{ cm}$. Optical probes were secured to the infant's head with thick, wide tracheostomy ties, or with soft elasticised bandage material secured with Velcro fasteners.

2.3 Image reconstruction

The images were reconstructed assuming that the contour of the scalp was relatively flat and that the scalp, skull, cerebrospinal fluid, and brain could be treated as a homogeneous, semi-infinite medium except for the region of activation. The optical properties outside the plane are assumed to be unchanged. Images were reconstructed in a plane approximately equal to the size of the grid, positioned at a depth of 10 mm and with a thickness of 1 mm. The voxel size was $3 \times 2 \times 1 \text{ mm}$. This plane was parallel to the plane of sources and detectors. With this geometry, images were reconstructed using synchronous iterative reconstructive technique (SIRT) [17]. Images were pro-

duced and displayed on the computer monitor in approximately real-time fashion. Ten iterations of SIRT was used for reconstruction.

2.4 Optical imaging protocol (1)

All clinical studies were performed under an institutional review board-approved protocol, and parents signed informed consent prior to initiation of studies. For the initial studies, two extremely ill premature infants underwent passive motor stimulation and optical functional imaging. The patients were quiet and asleep, but not pharmacologically sedated or paralyzed. The infants were 75 day old former 24 week estimated gestational age (EGA) male twins, both of whom had had complicated hospital courses and were mechanically ventilated at the time of the studies. Both had normal heart rates and O₂ saturations as determined by pulse oximetry during the approximately 40 minute study periods. There were no complications from probe placement.

For these initial studies, the smaller prototype probe was placed approximately medially above the region infant brain, which corresponded to the motor cortex (figure 1). However, due to the small size of the probe, it was positioned in such a way as to include a larger area of the motor cortex contralateral to the side of arm movement. Baseline data was collected for 20 seconds. Then, based on ease of access to the patient, the left or right arm was flexed and extended at the elbow by the examiner at a frequency of approximately 1 Hz. For these first studies, passive motor stimu-

lation continued for 20 seconds, followed by a 20–45 second resting period, then stimulation was re-initiated. Data was averaged over the entire 20 second stimulation period, which represented seven independent cycles of the sources. Data for these first studies were collected only at 830 nm.

2.5 Optical imaging protocol (2)

With further probe and software development, additional studies were undertaken. As with the previous protocol, all studies were carried out under an IRB-approved protocol, and informed consent was obtained prior to the initiation of the studies. For these studies, 3 two to three week old 32–33 week EGA infants underwent a similar passive motor stimulation protocol. The infants were quiet and asleep, but not pharmacologically sedated or paralyzed. These infants had had hospital courses which included short periods of intubation and mechanical ventilation or continuous positive airway pressure, but all were extubated and on room air or nasal cannula oxygen at the time of the studies. All patients had normal heart rates and O₂ saturations by pulse oximetry during the approximately 40 minute study period. There were no complications from probe placement.

For these studies, a larger probe was developed and it was placed in true midline position in the region that corresponded to the motor cortex (figure 2). Baseline data was again collected for 20 seconds, then the patient right or left arm was flexed and extended at the elbow. These studies

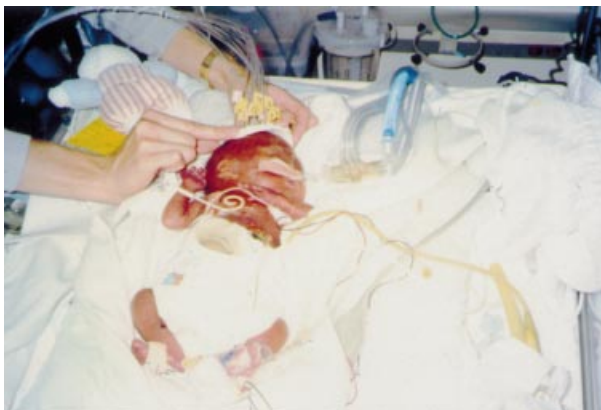

Figure 1. Prototype fiberoptic probe being placed on a 75 day old, former 24 week EGA infant.

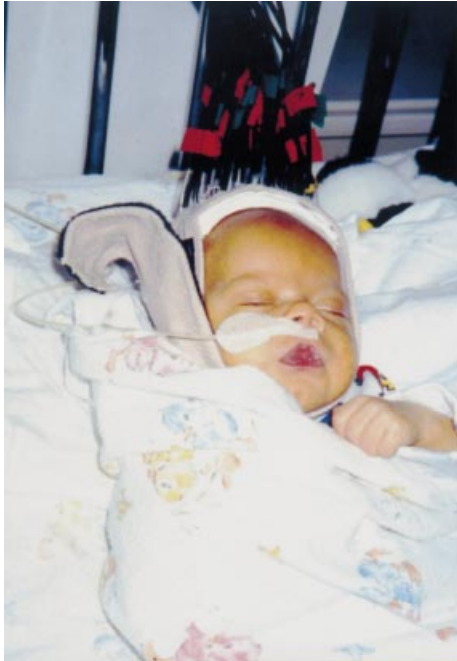

Figure 2. Advanced prototype fiberoptic probe in place on 3 week old, former 32 week EGA infant.

employed a 5 second integration time instead of averaging over 20 seconds, and each stimulation period was increased to 30 seconds with a correspondingly longer rest period of 45–60 seconds between each stimulation period. In addition, data were collected at both 780 nm and 830 nm.

3 Results

3.1 Optical protocol (1) results

Representative images for the first study protocol are shown in figure 3. A probe placement diagram is shown at the top of the figure. The first optical image on the left shows the control (“rest”) image, where very little variation is identified. The next two images show different activation maps, similar in appearance to topographical weather maps, obtained 5 minutes apart. Using 830 nm only, increased absorbance on the left, as seen by yellow to red color change, was noted consistently with passive motor stimulation on the right side, correlating with the contralateral motor cortex. This change in absorbance at

830 nm could be consistent with increased blood flow and oxygenation in that region. While the images are qualitatively similar, the activation map at each time period is slightly different. Also, some increased absorption is noted in the ipsilateral motor cortex area as well. Due to the small probe size during these studies, however, it was not possible to investigate this finding simultaneously with contralateral motor cortex during stimulation.

3.2 Optical protocol (2) results

Representative images are shown in figure 4. During these studies, both 780 nm and 830 nm wavelengths were used. As seen on the second row of images, there are clear increases in absorbance at 830 nm, indicated by the increase in yellow to red color, but also, as seen in the first row of images, much greater absorbance at 780 nm. Taken together, this data indicates an increase in blood volume to the imaged area, as well as an overall increase in deoxyhemoglobin concentration.

A graphic representation of the greater absorbance at 780 nm versus 830 nm is seen in figure 5A. These absorption coefficient changes associated with the stimulation were averaged from nine voxels from the centroid of contralateral activation. A spectroscopic analysis of these absorption coefficient changes yields the corresponding change in oxy- and deoxyhemoglobin [4, 5]. The increasing change in deoxyhemoglobin concentration (Hb) over time is shown in figure 5B. The slope of these changes appears to continue to increase beyond the period of stimulation.

4 Discussion

These data indicate that real-time, bedside functional imaging of the infant brain is feasible. Further, these initial studies reveal that, in a particular preterm population, cerebral regional blood volume and oxygenation patterns during passive motor stimulation appear to be different from those expected in an adult population based on previous functional imaging studies of neuronal activation [13, 19, 20]. Continued development of this non-invasive optical technique should lead to long-term investigations of

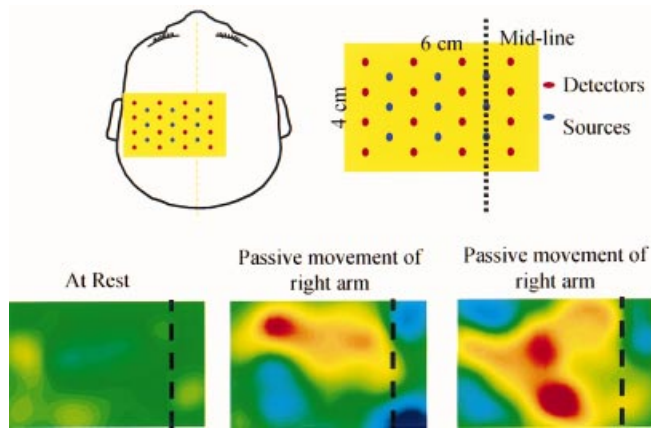


Figure 3. Representative DOTS functional images obtained using optical protocol (1) during passive movement of the right arm. Note increase in yellow to red color during passive motor stimulation indicating increased absorbance in the region of the motor cortex contralateral to the side of movement.

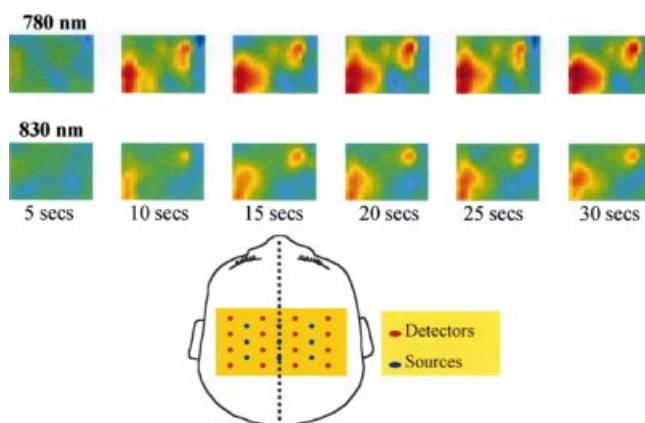


Figure 4. DOTS functional images obtained using optical protocol (2) during passive movement of the right arm. Images using this protocol were updated every five seconds. Greatest increasing absorbance at both 780 nm and 830 nm is noted with stimulation in the region of the motor cortex contralateral to the side of movement, however some increase in absorbance is also noted in the ipsilateral side.

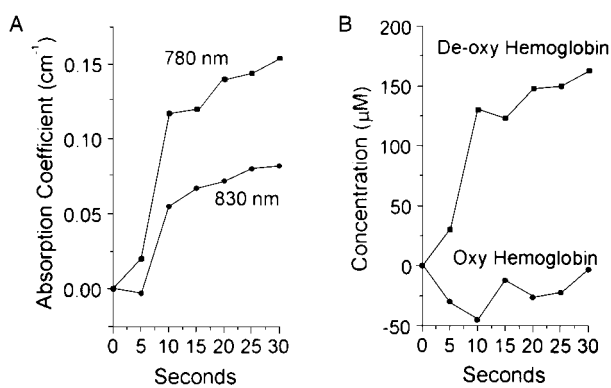


Figure 5. Graphic representation of absorption coefficient changes at 780 nm and 830 nm (at left), and oxyhemoglobin (HbO) and deoxyhemoglobin (Hb) (at right) over passive stimulation study time course.

infants at risk for subsequent neurodevelopmental abnormalities.

Despite a reduction in the preterm infant mortality rate due to advances in respiratory and cardiovascular support, the developmental pathways and mechanisms of injury of the infant brain remain poorly described. Premature infants are frequently critically ill, requiring maximum medical intervention, and are unable to be moved outside of the intensive care environment for radiologic studies. Invasive monitoring would not be tolerated, or in many cases, possible, in this patient population. Bedside brain imaging techniques, particularly cranial ultrasound, have made diagnoses of specific anatomic abnormalities possible. Certain ultrasound-diagnosed cranial abnormalities, such as grade III or IV intraventricular hemorrhage (IVH) or cystic periventricular leukomalacia (PVL) have been identified as prognostic indicators of abnormal neurodevelopmental outcome [7, 27, 33]. Long term follow up studies, however, indicate that the presence of IVH alone is a poor indicator of motor, cognitive and sensory impairment, whereas cerebral ischemia may be the more frequent culprit [31]. Efforts to identify preterm infants at risk for cystic PVL, and therefore potentially intervene before irreversible damage has been done, have revealed that most have had a relatively benign clinical course [26].

Therefore, many functional imaging modalities such as MRI have been used to evaluate and correlate functional outcome in neonatal leukomalacia [3] as well as brain development in preterm infants [14]. Also, due to the phenomenon of decreased cerebral blood flow with hyperventilation, fMRI has been used to assess local cerebral CO₂ reactivity in preterm and distressed term infants [32], demonstrating local impairment of CO₂ reactivity as compared with adults. SPECT functional imaging of infants with West syndrome revealed subtle areas of cerebral hypoperfusion not seen with other imaging techniques [15]. In infants who have undergone extracorporeal membrane oxygenation (ECMO), SPECT revealed subtle abnormalities in rCBF soon after ECMO therapy ended [25]. Similarly, rCBF abnormalities have been revealed in infants who have undergone complex cardiovascular surgery using SPECT [6]. It has

also been suggested that functional imaging techniques may be a helpful tool in the diagnosis of neuromigrational disorders and the evaluation of functional focal abnormalities associated with seizure activity, even in the presence of a normal MRI [16].

Although these studies have identified important subclinical injuries in these patients, MRI, PET and SPECT scans cannot be performed to make moment to moment assessments, cannot currently be used as monitoring devices, and generally reveal damage or changes that have already occurred. A better functional imaging method would include bedside, continuous monitoring to allow for intervention in response to changes in rCBF and oxygenation. This would be especially important in the high-risk population, such as neonatal cardiovascular surgical patients, where the prevalence of subsequent neurological problems may approach 25% [8]. With the advent of neuroprotective agents on the horizon, real-time functional monitoring will be essential. The system used in the studies presented here, DOTS, has the advantages of functional imaging, i. e. measurement of changes in regional total hemoglobin and cerebral oxygenation, with the benefits afforded by portability, non-invasiveness, and potential as a continuous monitoring device supported by real-time image production. These aspects of the device are of particular importance to the premature and extremely ill term infant population, in which transport to a PET or MRI facility is not feasible. Furthermore, such an exam would simply represent a "snap shot" for the medically unstable patient in question.

Although the initial studies with a single wavelength may be seen as feasibility studies, the secondary studies with two wavelengths revealed relative decreases in regional oxygenation over the period of stimulation. This is similar to what is referred to in the fMRI literature as an inverse blood oxygen level dependent (inverse BOLD) effect. As opposed to adults, who show increased BOLD fMRI signal and therefore decreased deoxyhemoglobin concentration and increased blood flow in corresponding areas of the brain during stimulation, recent studies have shown decreased BOLD fMRI signal during visual stimulation in infants and young children [1]. Similar

results have been reported using NIRS techniques to evaluate hemodynamic responses to visual stimulation in infants [21]. This difference has been speculated to be due to a higher proportional increase in oxygen extraction relative to increased rCBF during activation, but further studies are required to elucidate the precise mechanism.

In addition, further changes and improvements in future DOTS clinical studies should be considered. First, although improved images were achieved following a change to a larger probe design during our secondary studies, further evaluation of the areas of activation is needed. To that end, probe design and hardware improvements are in progress, including larger probe detector array, and additional laser wavelengths. Specifically, the extent of ipsilateral activation and causation of quantitative changes in the motor activation map over time requires further study. One speculation is that this ipsilateral activation represents activation of nonprimary motor areas in the cortex, as has been reported in adult studies of motor activation using PET and MRI [10, 24]. Of note, in movement protocols in which unilateral movements were compared with rest, as in the protocol used in the present study, ipsilateral activation was also noted in a recent functional MRI study [24]. Second, design of the appropriate stimulation protocol is a challenging issue. The neonatal population is extraordinarily difficult to study in this regard; unlike adults and children, they obviously do not respond to commands, and unfortunately are easily disturbed. The present protocols were designed in order to minimize any potentially confounding effects of sedative agents or neuromuscular blockade. However, future

studies with infants may require sedation as a longer stimulation time will be needed to evaluate the continued increase in deoxyhemoglobin concentration change seen in the present studies. In addition, timing of recovery of absorption to baseline after stimulation could be an important additional factor to explore. Finally, relatively little is known regarding "normal" functional imaging changes in the neonate over time and gestation. Many patients of differing gestational and actual age, as well as acuity of illness, will need to be studied as part of a multicenter initiative in order to create a "library" of optical functional images in the neonate. Certainly, functional imaging changes have been shown over maturation using SPECT in previous studies by Rubinstein et al. [29]; regional blood volume or oxygenation changes over gestational age and actual age would not be unexpected findings using optical functional imaging techniques. The present study is clearly complicated by the fact that the infants studied are of very different gestational age, actual ages, and severity of illness. It is therefore presented to demonstrate the potential of a new, real-time, non-invasive system, and is merely a start to the "library" of images that will be needed to draw more informed conclusions about the function of the premature brain.

Functional imaging using near-infrared techniques requires and deserves further study, especially in the preterm and term infant. Given our limited understanding of the exact causation and pathophysiology of, and therefore preventative measures for significant neonatal neurodevelopmental damage such as cerebral palsy [9], continued studies focusing on real-time and continuous regional blood volume and oxygenation changes are warranted.

Abstract

Background: Changes in regional brain blood flow and hemoglobin oxygen saturation occur in the human cortex in response to neural activation. Traditional functional radiologic methods cannot provide continuous, portable measurements. Imaging methods, which use near-infrared light allow for non-invasive measurements by taking advantage of the fact that hemoglobin is a strong absorber at these wavelengths.

Aims: To test the feasibility of a new optical functional imaging system in premature infants, and to obtain pre-

liminary brain imaging of passive motor activation in this population.

Methods: A new optical imaging system, the Diffuse Optical Tomography System (DOTS), was used to provide real-time, bedside assessments. Custom-made soft flexible fiberoptic probes were placed on two extremely ill, mechanically ventilated 24 week premature infants, and three healthier 32 week premature infants. Passive motor stimulation protocols were used during imaging.

Results: Specific movement of the arm resulted in reproducible focal, contralateral changes in cerebral absorption. The data suggest an overall increase in blood volume to the imaged area, as well as an increase in deoxyhemoglobin concentration. These findings in premature infants differ from those expected in adults.

Conclusions: In the intensive care setting, continuous non-invasive optical functional imaging could be critically important and, with further study, may provide a bedside monitoring tool for prospectively identifying patients at high risk for brain injury.

Keywords: Brain, functional imaging, infant, near-infrared, neonate, optical.

Abbreviations: fMRI: Functional MRI, PET: Positron Emission Tomography, SPECT: Single Photon Emission Computed Tomography, TOFA: time-of-flight and absorbance, DOTS: Diffuse Optical Tomography System, rCBF: regional cerebral blood flow

Acknowledgements: The authors wish to thank Professor A. H. Schwettman and Ms. Siv Modler for their assistance. Work supported by United Cerebral Palsy Foundation, ONR H-00014-91-C0170, NIH/NINDS SBIR support to the Spectros Corporation (N43-NS-6-2313 and -2315) and General Clinical Research Centers MO1-00070. DA Boas acknowledges support from Center for Minimally Invasive Therapies, and NIH/NINDS (NIH 1 N29 NS38842 AO1).

References

- [1] Born P, H Leth, MJ Miranda, E Rostrup, A Stensgaard, B Peitersen, HBW Larsson, HC Lou: Visual activation in infants and young children studied by functional magnetic resonance imaging. *Pediatr Res* 44 (1998) 578
- [2] Chance B, E Anday, S Nioka, S Zhou, L Hong, K Worden, C Li, T Marray, Y Ovetsky, D Pikiditi, R Thomas: A novel method for fast imaging of brain function, non-invasively, with light. *Optics Express* 2 (1998) 411
- [3] Cioni G, L Bartalena, E Biagioni, A Boldrini, R Canapicchi: Neuroimaging and functional outcome of neonatal leukomalacia. *Behav Brain Res* 49 (1992) 7
- [4] Cope M, DT Delpy: System for long-term measurement of cerebral blood flow and tissue oxygenation on newborn infants by infra-red transillumination. *Med Biol Eng Comput* 26 (1988) 289
- [5] Cope M: The development of a near-infrared spectroscopy system and its application for noninvasive monitoring of cerebral blood and tissue oxygenation in the newborn infant. London University College Press, London 1991
- [6] du Plessis A, S Treves, P Hickey, L O'Tuama, C Barlow, J Costello, A Castaneda, D Wessel: Regional cerebral perfusion abnormalities after cardiac operations. *J Thor and Cardiovasc Surg* 107 (1994) 1036
- [7] Fazzi E, G Lanzi, A Gerardo, A Ometto, S Oresci, G Rondini: Neurodevelopmental outcome in very-low-birth-weight infants with or without periventricular haemorrhage an/or leucomalacia. *Acta Paediatr* 81 (1992) 808
- [8] Ferry P: Neurologic sequelae of open-heart surgery in children: an irritating question. *Am J Dis Child* 144 (1990) 369
- [9] Filloux F: Neuropathophysiology of movement disorders in cerebral palsy. *J Child Neurol* 11 (1996) S5
- [10] Fink GR, RSJ Frackowiak, U Pietrzyk, RE Passingham: Multiple nonprimary motor areas in the human cortex. *J Neurophysiol* 77 (1997) 2164
- [11] Hintz SR, DA Benaron, R Robbins, J Duckworth, A Murphy, J Price, F Liu, DK Stevenson, W-F Cheong: Brain functional imaging using time-of-flight optical spectroscopy. *SPIE Proc* 3194 (1997) 176
- [12] Hintz SR, W-F Cheong, JP van Houten, DK Stevenson, DA Benaron: Bedside imaging of intracranial hemorrhage in the neonate using light: comparison with ultrasound, computed tomography, and magnetic resonance imaging. *Pediatr Res* 45 (1999) 54
- [13] Hoshi Y, M Tamura: Dynamic multichannel near-infrared optical imaging of human brain activity. *J Appl Physiol* 75 (1993) 1842
- [14] Huppi P, B Schuknecht, C Boesch, E Bossi, J Fellingner, C Fusch, N Herschkowitz: Structural and neurobehavioral delay in postnatal brain development of preterm infants. *Pediatr Res* 39 (1996) 895
- [15] Hwang P, H Otsubo, B Koos, D Gilday, S Chuang, V Jay, J Hoffman: Infantile Spasms: Cerebral blood flow abnormalities correlate with EEG, neuroimaging, and pathologic findings. *Pediatr Neurol* 14 (1996) 220
- [16] Iannetti P, A Spalice, G Atzei, S Boemi, G Trasimeni: Neuronal migrational disorders in children

- with epilepsy: MRI, interictal SPECT and EEG comparisons. *Brain Dev* 18 (1996) 269
- [17] Kak AC, M Slaney: Principles of computerized tomographic imaging. IEEE Press, New York 1988
- [18] Kawashima R, M Matsumura, N Sadato, E Naito, A Waki, S Nakamura, K Matsunami, H Fukuda, Y Yonekura: Regional cerebral blood flow changes in human brain related to ipsilateral and contralateral complex hand movements – a PET study. *Eur J Neuro* 10 (1998) 2254
- [19] Kleinschmidt A, H Obrig, M Requardt, KD Merboldt, U Dirnagl, A Villringer, J Frahm: Simultaneous recording of cerebral blood oxygenation changes during human brain activation by MRI and near-infrared spectroscopy. *J Cereb Blood Flow Metab* 16 (1996) 817
- [20] Kwong KK: Functional magnetic resonance imaging with echo planar imaging. *Magn Reson Q* 11 (1995) 1
- [21] Meek JH, M Firbank, CE Elwell, J Atkinson, O Braddick, JS Wyatt: Regional hemodynamic responses to visual stimulation in awake infants. *Pediatr Res* 43 (1998) 840
- [22] Nioka S, Q Luo, B Chance: Human brain functional imaging with reflectance CWS. *Adv Exp Med Biol* 428 (1997) 237
- [23] Olesen J: Contralateral focal increase of cerebral blood flow in man during arm work. *Brain* 94 (1971) 635
- [24] Papke K, P Reimer, B Renger, G Schuierer, S Knecht, M Schulz, W Heindel: Optimized activation of the primary sensorimotor cortex for clinical functional MR Imaging. *AJNR* 21 (2000) 395
- [25] Park C, A Spitzer, H Desai, J Zhang, L Graziani: Brain SPECT in neonates following extracorporeal membrane oxygenation: evaluation of technique and preliminary results. *J Nucl Med* 33 (1992) 1943
- [26] Perlman JM, R Risser, RS Broyles: Bilateral Cystic Periventricular leukomalacia in the premature infant: associated risk factors. *Pediatrics* 97 (1996) 822
- [27] Piecuch RE, CH Leonard, BA Cooper, SA Sehring: Outcome of extremely low birth weight infants (500 to 999 grams) over a 12-year period. *Pediatrics* 100 (1997) 633
- [28] Risberg J, DH Ingvar: Patterns of activation in the grey matter of the dominant hemisphere during memorizing and reasoning. A study of regional cerebral blood flow changes during psychological testing in a group of neurologically normal patients. *Brain* 96 (1973) 737
- [29] Rubinstein M, R Denays, H Ham, A Peipsz, T VanPachterbeke, D Haumont, P Noel: Functional imaging of brain maturation in humans using iodine-123 iodoamphetamine and SPECT. *J Nucl Med* 30 (1989) 1982
- [30] Siegel AM, JJA Marota, DA Boas: Design and evaluation of a continuous-wave diffuse optical tomography system. *Optics Express* 4 (1999) 287
- [31] Stewart A, E Reynolds, P Hope, P Hamilton, J Baudin, A Costello, B Bradford, J Wyatt: Probability of neurodevelopmental disorders estimated from ultrasound appearance of brains of very preterm infants. *Dev Med Child Neurol* 29 (1987) 3
- [32] Toft P, H Leth, H Lou, O Pyrdys, B Peitersen, O Henriksen: Local vascular CO₂ reactivity in the infant brain assessed by functional MRI. *Pediatr Radiol* 25 (1995) 420
- [33] Wilkinson I, J Bear, J Smith, A Gill, C Challinor, W Jones, M Shahidullah, S Wooderson: Neurological outcome of severe cystic periventricular leukomalacia. *J Paediatr Child Health* 32 (1996) 445

Received August 2, 2000. Revised December 11, 2000. Accepted January 2, 2001.

Susan R. Hintz, M. D.
 Assistant Professor of Pediatrics
 Division of Neonatal and Developmental Medicine
 Stanford University School of Medicine
 750 Welch Road, Suite 315
 Palo Alto, CA 94304 U. S. A
 Tel: +1650-723-5711
 Fax: +1650-725-8351
 email: srhintz@stanford.edu